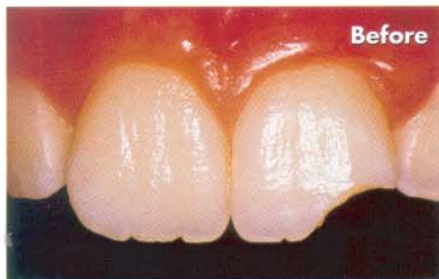
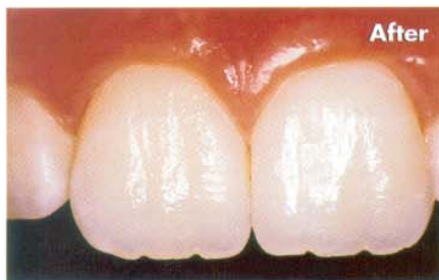
Restoring a fractured maxillary central incisor using Matrixx Anterior hybrid composite

By Dr. Newton Fahl Jr., Curitiba, Brazil. Information provided by Discus Dental Inc.



Fractured upper left maxillary central incisor.



The completed restoration.

Following are step-by-step procedures for a mixed technique using Matrixx Anterior Hybrid composite for the restoration of a fractured maxillary central incisor.

Case presentation

An 11-year old female patient presented with a fractured upper left maxillary central incisor (Tooth No. 9) showing pulp vitality upon testing (see “Before” figure). The tooth fragment was not kept for bonded reattachment.

1. Make a silicone matrix off a waxed-up model (Fig. 1). *Note:* The matrix allows proper incremental placement of composite and incisal edge position during the restorative procedure. It also aids in visually determining the length of the dentinal mamelons and the extent of the surrounding translucent and opalescent incisal shades, the length of the dentinal mamelons, and the extent of the surrounding translucent incisal shades.

2. Using a #1111 flame-shaped medium-grit diamond (KG Sorensen), place both a facial bevel of approximately 2.5 mm (that extends from the dentin-enamel junction to the outer surface of the

tooth) and a shorter lingual chamfer. *Note:* Generally, the larger the fracture, the longer the bevel required.

3. Round off the facial bevel finish line to make it “infinite” (Fig. 2).

4. Isolate with rubber dam, using a modified technique for adequate field control.

5. Sand-blast all enamel and dentin surfaces with an Micro-etcher II intraoral sandblaster (Danville Engineering),¹ and rinse thoroughly with copious water spray.

6. Etch the dentin first and then the enamel with Gel Etchant 37.5% phosphoric acid gel (Kerr). Rinse thoroughly approximately 10 to 15 seconds from completion of the etching procedure. Remove excess water with vacuum suction for five seconds to avoid desiccation (Fig. 3).

7. Apply Discus Dental Cabrio hydrophilic adhesive (Fig. 4). *Note:* Regardless of the adhesive system employed, the author recommends that the bonding agent must be used following a strict protocol to ensure penetration and thorough saturation of the partially demineralized zone of the dentin, to maximize bond strength, and to minimize microleakage.

ABOUT: Matrixx®

Anterior hybrid (AH) composite

Features

- Available in 22 Color Perfect shades: 13 body shades, three enamel bleach shades, an opaque A2 shade, white, and four incisal shades
- Special blend of fillers



- Exceptional polishability, surface smoothness
- Blend of finishing and polishing properties
- 0.7µm average particle size, 81% filled by weight
- Exceptional compressive strength
- Low water absorption

- Simulates, maintains anatomical contours

Manufacturer

Discus Dental Inc.
8550 Higuera St.
Culver City, CA 90232
Telephone: 800-422-9448
Fax: 310-845-1537
www.discusdental.com

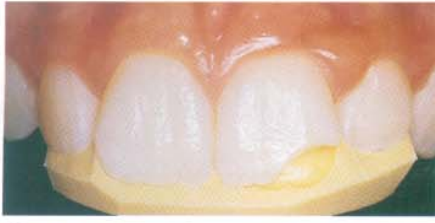

Fig. 1 Make a silicone mold off a waxed up model.

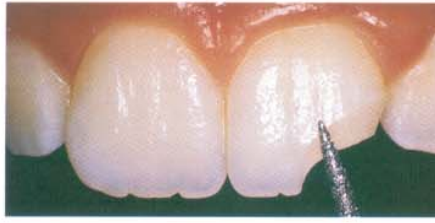

Fig. 2 Round off the facial bevel finish line.

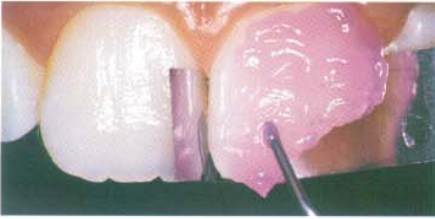


Fig. 3 Acid etch enamel and dental surfaces.

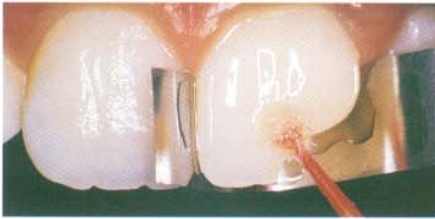


Fig. 4 Apply Cabrio hydrophilic adhesive.

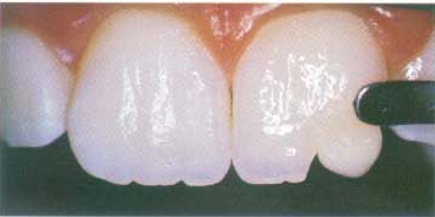

Fig. 5 Slightly feather an increment of composite.

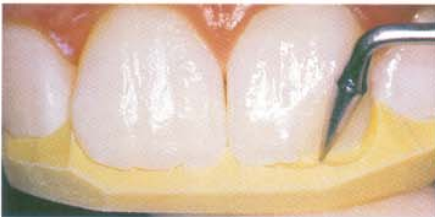

Fig. 6 Position silicone matrix and sculpt anatomy.

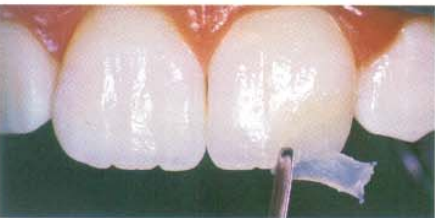

Fig. 7 Apply Matrixx anterior hybrid Bleach 2.

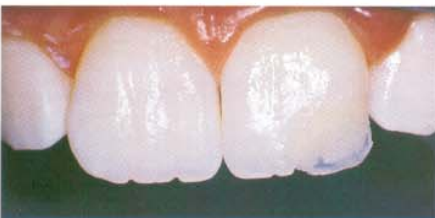

Fig. 8 Apply opacous material.

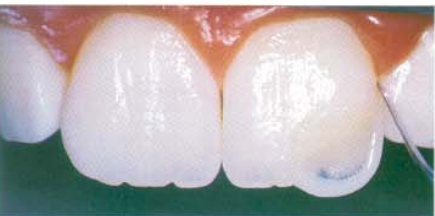

Fig. 9 Tack artificial enamel body shade.

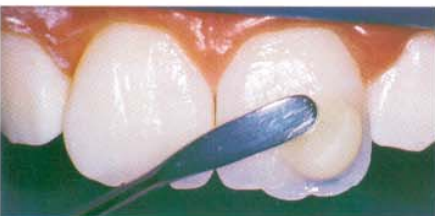

Fig. 10 Apply a final layer of Matrixx anterior microfill medium incisal composite.

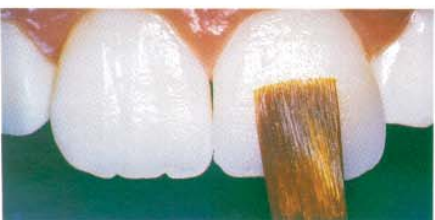

Fig. 11 Refine lingual morphology.

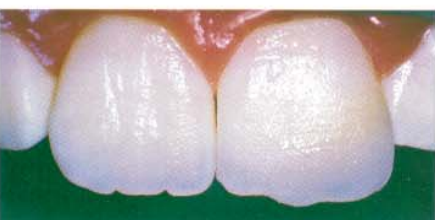

Fig. 12 Contour the restoration until desired primary anatomy is established.

8. Because of the size of the fracture in this case, build-up the artificial dentin in one small increment (no thicker than 2 mm facio-lingually) for better control over the desired anatomy and to guarantee complete polymerization.²

9. To start blending-in the composite resin, lightly feather an increment of a high-chroma shade of Matrixx Anterior Hybrid composite onto the beveled facial and lingual enamel (Fig. 5).

10. Securely position the silicone matrix and sculpt the mamelon anatomy with a Hollenback #6 pointed instrument (SS White). Allow sufficient room for the artificial enamel along the incisal edge and around the distal point angle (Fig.6).

11. Polymerize the increment for 10 seconds with an Optilux 501 halogen curing unit (Demetron/Kerr) set on boost mode.

12. Achieve the desired cervico-incisal length of the tooth using the silicone mold as a reference. First lay a more translucent incisal shade (Matrixx Anterior Hybrid Medium Incisal) along the incisal ridge, between the mamelons and around the inciso-proximal edges, slightly covering the mamelon lobes labio-palatally. Sculpt accordingly.

13. Achieve an opalescent halo effect by applying a semi-translucent milky-white shade (Matrixx anterior hybrid Bleach 2) material around the translucent incisal shade. This builds a “frame” of material to establish a point of reference for the subsequent layers of composites to be applied labially, proximally, and palatally (Fig. 7).

14. Apply opacous material over and along the tooth-composite interface to disguise the fracture line. Use one of the following three choices to accomplish this step: 1) a higher opacity hybrid, 2) an opaquar,³ or 3) a higher opacity microfilled composite.⁴ *Note:* In this clinical situation, the author used a thin layer of an opaque shade of Matrixx Anterior Microfill Opaque Shades microfill composite bearing the same hue and chroma of the final body artificial enamel microfill over the artificial dentin to create a subtle gradient from tooth to composite build-up (Fig. 8).

15. Implement and tack the artificial enamel body shade one increment to the facial aspect (Fig. 9). *Note:* To obtain proper facial contour and proximal contact, spread the enamel shade to veneer the underlying “frame” cervico-incisally and mesio-distally, sculpting and finessing to

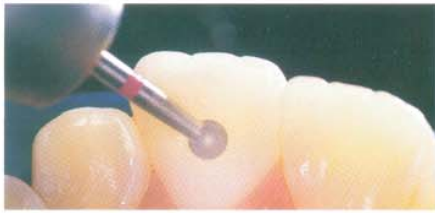


Fig. 13 For secondary anatomy, use 12-fluted carbide finishing burs.

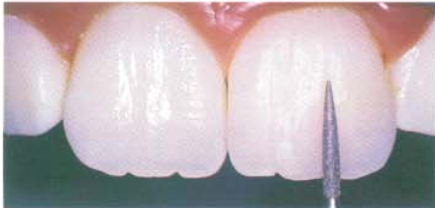

Fig. 14 Use a flame-shaped diamond for surface texturization.

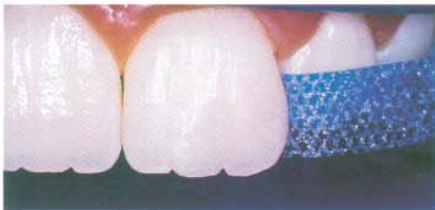

Fig. 15 Complete interproximal finishing and polishing.

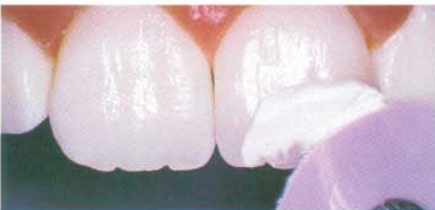

Fig. 16 Polish and buff to impart a high shine.

proper anatomical form with the aid of artist brushes.

16. To impart an enamel-like translucency to the restorations, apply a final layer of Matrixx anterior microfill medium incisal composite to the incisal third and sculpt to the desired morphology (Fig. 10).

17. Accomplish proper lingual embrasure form and proximal contact by placing a mylar strip interproximally, sculpting marginal ridge anatomy, and pulling the matrix through the interproximal contact in a linguo-facial direction.

18. After appropriate refinement of lingual morphology with contouring instruments and artist brushes (Fig. 11), cover the labial and lingual aspects of the restoration with an oxalate gel for oxygen inhibition, additionally light cure for 60 seconds.

19. At this stage, check the restoration for morphological refinement, width-to-length ratio, embrasure forms, and line angles, and ready for finishing and polishing.

20. Contour the restoration with Sof-Lex LT coarse aluminum oxide disks (3M Dental) until the desired primary anatomy is established (Fig. 12).

21. To guide the attainment of symmetrical light-reflecting areas, draw lines along the ideal position of the proximo-labial line angles.

22. For secondary anatomy (developmental grooves, lobes, cingulum, and marginal ridges) use #7901 and #7404 Art & Science of Dentistry 12-fluted carbide finishing burs (Kerr) (Fig. 13).

23. Use #7901 and #7404 Art & Science

of Dentistry fine-grit flame-shaped diamonds⁵ (Kerr) to accomplish surface texturization (Fig. 14).

24. Use Compo-Strips diamond (Premier) and Epitex plastic strips (GC America) for interproximal finishing and polishing (Fig. 15).

25. Buff the whole restoration with Flexi-Cup polishing cups and Flexi-Point points (Cosmedent) to eliminate some of the undesired accentuated texturization.

26. Use Enamelize composite polishing paste (Cosmedent) and a Flexibuff buffing disk (Cosmedent) to impart a high shine to the restoration surface while still retaining the designed surface texture (Fig. 16).

27. After final polishing, further light cure the restoration for 60 seconds.⁶ The result was a highly esthetic, functional restoration that presented total bio-integration with the surrounding natural tooth structure. A true reproduction of tooth morphology and color is achieved by using the meticulous application of a composite layering technique (See "After" figure, on first page). **DPR**

References

1. Roeder, L.B., Berry, III, E.A., You, C. and Powers, J.M. Bond Strength of Composite to Air-abraded Enamel and Dentin, *Operative Dentistry*, (20)186 - 190, 1995.
2. Rueggeberg, F.A., Caughman, W. F., Curtis, J.W. and Davis, H.C. A Predictable Model for the Polymerization of Photo-activated Resin Composites. *The International Journal of Prosthodontics*, 7(2)159-166, 1994.
3. Mopper, W R. Renamel System
4. Fahl, N.J. Class IV. California dental association
5. Croll, T.P. Simulating Irregular Enamel Surface Texture in Composite Resin Restorations. *Quintessence Int* 19:311, 1988.
6. Goldstein, Renamel System.

